

Removal of Large Sized Ovarian Cysts by Potentized Homeopathic Remedies: A Myth or a Dependable Alternative Option

Abstract

Removal of large sized ovarian cysts by homeopathic treatment is generally not considered as a dependable option vis-a-vis removal via surgery. In this communication, we present three authentic cases of successful removal of big sized ovarian cysts by administration of a single potentized homeopathic remedy, Apis mellifica, selected on the basis of totality of symptoms, and authenticated with the aid of ultrasonographic as well as hormonal studies.

Keywords: Human; Ovarian cyst removal; Homeopathy; Apis mellifica; Ultrasonography; Hormones

Case Report

Volume 3 Issue 5 - 2016

Debarshi Das¹, Asmita Samadder², Saroj Kumar Kayal¹ and Anisur Rahman Khuda-Bukhsh^{3*}

¹Mahesh Bhattacharyya Homeopathic Medical College and Hospital, India

²Department of Zoology, Dum Dum Motijheel College, India

³UGC Emeritus Fellow, Kalyani University, India

***Corresponding author:** Anisur Rahman Khuda-Bukhsh, UGC Emeritus Fellow at University of Kalyani, B-2/325, Kalyani, Husn-Ara Manzil, Kalyani-741235, West Bengal, India, Tel: 919331040032; Email: prof_arkb@yahoo.co.in, khudabukhsh_48@rediffmail.com

Received: April 19, 2016 | **Published:** May 12, 2016

Abbreviations: µg: Microgram; AM: After Medicine; BM: Before Medicine; DHEAS: Dehydroepiandrosterone sulphate; dl: Decilitre; E2: Estradiol; F: Fasting; FSH: Follicle Stimulating Hormone; IU: International Unit; LH: Leutinizing Hormones; mg: Milligram; ml: Millilitre; ng: Nanogram; pg: Picogram; PP: Post Prandial;

Introduction

An ovarian cyst can be defined as a collection of fluid surrounded by a very thin wall within an ovary; any follicle larger than about two centimetres is termed as an ovarian cyst [1], and they vary in size from a pea (small) to much larger size, almost that of an orange. Although they are mostly found in women of reproductive age and most of them are harmless or benign in nature they are reported occasionally to cause severe pain in the abdomen with menstrual irregularities and cause excessive bleeding. In such cases when the cyst size is causing concern not only for its increasing size but also for causing certain undesirable symptoms like dull aching or sudden sharp stitching pain in lower abdomen, pain during coition or even during bowel movements it has to be treated with some seriousness; it also sometimes gives a full or bloated feeling after eating a small meal and also produces a constant nauseating or vomiting tendency. If patients with these symptoms visit an orthodox medical practitioner or surgeon, they are generally advised for surgical intervention to save the patient from further unwanted sufferings. There is a lack of confidence in both the patients and also in less experienced homeopathic practitioners to decide, particularly when the cyst size is alarming, if the patient should undergo surgical intervention or can undertake homeopathic course of treatment. Lack of many published case reports on successful removal of large sized ovarian cysts indicating efficacy of specific homeopathic remedies without necessity of any surgical intervention, is the main cause

of such a dilemma. Thus, there is a need for documentation of cases of successful removal of cysts, preferably by well selected single homeopathic remedy. Practitioners of orthodox medicines or surgeons also find some cases where even after surgical intervention, there may be development of fast growing tissue with the risk of leading it to cancer at the site of surgical incision [2,3]. However, such cases are relatively few.

For the treatment of large ovarian single cysts, homeopathic remedies are selected by taking into consideration totality of symptoms and based further on individualization of the particular patient in consultation with the repertorial rubrics [4] (Table 1). Several drugs are effectively used in different patients depending on their totality of symptoms and particularly taking into consideration some "repertorial guiding symptoms" [4-6] (Table 1); the most commonly used drugs are Apis mellifica, Belladonna, Lachesis, Arsenicum alb, Thuja etc. [4] (Table 1), of which Apis mel patients have typical symptoms as mentioned in Allen [5] and Boreicke [6] which can clearly distinguish them from that of the other drugs.

The patients with ovarian cysts generally manifest some typical symptoms like-feeling of congestion in the abdomen with right- or left-sided soreness in the inguinal region; have a feeling of stinging, burning and sore sensation [4-6]. Along with these, sometimes, they report complaint of tightness of the chest with an urge to urinate, occasionally with burning sensation in urine, bearing down sensation as if menses were to appear, sensitive and tenderness over abdomen. Patients experience amelioration of these symptoms by cold water application and warmth often aggravates. In course of our extensive studies being carried out on patients with ovarian single cysts and multiple cysts [7,8], we are reporting here three cases of patients, who presented typical guiding symptoms that agreed well and justified with the selection of Apis mellifica as the single remedy without any ambiguity.

Table 1: Kent’s Repertory with chapter, page number and concerned rubric indicating Apis mel to be the first drug of choice for all three patients.

Symptoms	Symptoms References with Grade and Medicines	Chapter	Page No
Tumour Ovaries	<p>Tumors <i>Calc., coc-c., Lyc., nit-ac.</i> encysted : Bar-c., calc., carb-s., <i>graph.</i>, kali-c., lyc., nit-ac., rhod., <i>sabin.</i>, sep., <i>sil.</i>, sulph. erectile : Ars., <i>carb-an.</i>, <i>carb-v.</i>, kreos., <i>lach.</i>, lyc., <i>nit-ac.</i>, <i>phos.</i>, plat., sep., <i>sil.</i>, sulph., <i>thuj.</i> bleeding : Arn., coc-c., kreos., <i>lach.</i>, <i>phos.</i>, puls., <i>thuj.</i> blue : <i>Carb-v.</i> burning : Calc., <i>carb-an.</i>, <i>thuj.</i> itching : <i>Nit-ac.</i> pricking : <i>Carb-v.</i> sticking : <i>Nit-ac.</i> hard : <i>Carb-v.</i></p> <p>Ovaries <i>Apis*</i>, apoc., ars-i., <i>ars.</i>, <i>bar-m.</i>, <i>calc.</i>, <i>coloc.</i>, fl-ac., <i>graph.</i>, hep., <i>iod.</i>, Lach., Lyc., <i>plat.</i>, <i>podo.</i>, staph., stram., syph., <i>zinc.</i> right : <i>Apis*</i>, fl-ac., <i>iod.</i>, Lyc., <i>podo.</i> left : Lach., <i>podo.</i> cysts : <i>Apis*</i>, <i>bov.</i>, <i>bufo.</i>, canth., carb-an., <i>coloc.</i>, <i>iod.</i>, <i>kali-br.</i>, <i>lach.</i>, merc., murx., <i>plat.</i>, prun-s., rhod., <i>rhus-t.</i>, <i>thuj.</i> fibroids : <i>Apis.</i>, calc., <i>coloc.</i>, fl-ac., hep., <i>iod.</i>, <i>lach.</i>, merc., <i>plat.</i>, <i>podo.</i>, staph., <i>thuj.</i></p>	Genitalia female	745
Swollen Ovaries	<p>SWOLLEN <i>Am-c.</i>, <i>ambr.</i>, <i>apis.</i>, arn., ars-i., Ars., <i>asaf.</i>, aur-m., aur-s., aur., bell., bry., calc-p., calc-s., <i>calc.</i>, cann-s., <i>canth.</i>, carb-an., <i>carb-v.</i>, coc-c., <i>coll.</i>, <i>coloc.</i>, con., dig., <i>ferr-i.</i>, goss., <i>graph.</i>, <i>helon.</i>, kali-bi., Kreos., <i>lac-c.</i>, <i>lach.</i>, <i>lil-t.</i>, meph., <i>merc.</i>, <i>nat-s.</i>, Nit-ac., nux-v., <i>phos.</i>, <i>podo.</i>, Puls., Rhus-t., sec., <i>sep.</i>, sulph., <i>thuj.</i>, <i>urt-u.</i>.....</p> <p>Ovaries : <i>Alum.</i>, <i>apis*</i>, <i>ars.</i>, atro., bell., <i>brom.</i>, <i>bufo.</i>, <i>carb-ac.</i>, coll., <i>coloc.</i>, con., cub., goss., <i>graph.</i>, ham., <i>iod.</i>, <i>kali-br.</i>, <i>kali-i.</i>, Lach., Lil-t., med., nat-h., nux-m., <i>pall.</i>, staph., syph., <i>thuja.</i>, <i>usti.</i>..... right : <i>Apis*</i>, lyc., <i>pall.</i> left : <i>Brom.</i>, carb-ac., <i>graph.</i>, kali-br., Lach., <i>lil-t.</i>, <i>nat-h.</i> menses, before : Brom. during : <i>Apis*</i>, brom., nat-h.</p>	Genitalia female	P-744
Pain in Right lower Abdomen stinging pain; sense of tightness; bearing-down	Tightness in ovarian region on raising arms : 2 nd grade symptoms <i>Apis</i>	Genitalia female	744
Touch Aggravation	Touch Aggravation- <i>Apis</i> 1 st grade	Generalities	1407
Urine scanty	Urine scanty 1 st grade symptoms- <i>Apis</i> 1 st grade	Urine	688
Vertigo on closing eyes	Vertigo : closing eyes :on <i>Apis</i> grade-2 symptoms	Vertigo	98
Vertigo on lying down	Vertigo : lying : while- <i>Apis</i> grade 2 symptoms	Vertigo	101
Burning urethra during	Constriction urinating during - <i>Apis</i> grade 2 symptom	Urethra	669
Warmth Aggravation	Warmth Aggravation <i>Apis</i> 1 st grade	Generalities	1412
Pressure Aggravation	Pressure Aggravation <i>Apis</i> 1 st grade	Generalities	1392

Case Presentation

Case study

The common general symptoms of all the three patients as well as minor individual deviations have been mentioned in Tables 2-4 for the three patients. All of them were confirmed cases of bearing large single cysts located in right ovary. They visited the clinic mainly with a complaint of nagging pain in the right abdominal region and some menstrual problem. They were first advised to perform trans-ovarian ultra-sonography (USG) at the earliest which they complied with. USG reports confirmed presence of large sized cysts in all of them.

Treatment

The detailed initial symptoms of the three patients, who visited the clinic on different dates, their prescriptions made, and their gradual symptomatic amelioration as well as hormonal data has been summarized in Table 2-5 and Figure 1-7. The USG images of the respective patients have been provided showing the status before the beginning of homeopathic drug administration and also after the treatment was complete (Figure 1-6), for patients 1-3, respectively. For statistical analysis of the hormonal data, standard student “t” tests were performed before and after administration of the homeopathic medicines.

Table 2: Details of symptoms, prescriptions, and improvements of the Patient No. 1 (Age: 19 years, unmarried).

Visit	Symptoms	Medicine Given	Period of Taking Medicine	Advised to Come After
First Visit 18.04.2015	USG showed mild diffuse fatty change of liver; bulky uterus, complex cyst in right ovary, size- 89.1 mmX56.1mm General symptoms: Sensation of stiffness and as of something torn off in the interior of the body; abdomen sore and stinging pains, pain in right lower abdomen; menses scanty, painful, dysmenorrhœa, with heaviness of lower abdomen; sense of tightness; bearing-down, as if menses were to appear; tenderness felt at perineum region; leucorrhœa at onset of menstruation; much prostration, and cannot concentrate her mind when attempting to read or study even a story book; vertigo on lying down or closing eyes; burning and soreness when urinating, pain and urine scanty. Modalities: Aggravated by warmth, touch and pressure; feels better in open air, and cold bathing;	Apis 30	Twice daily for 10 days (at least 45 minutes to 1 hr before or after any food) and Placebo for another 20 days	Advised to report after 30 days
20.05.2015	Improvement of her pain in the abdomen.	Placebo	1 month	1 month
19.06.2015	Feeling of weakness gradually improving; urinary symptoms also improved considerably.	Placebo	1 month	Advised to report after 30 days
22.07.2015	Once experienced moderate (bearable) pain with burning feeling in the urethra, in 1 st week of July2015.	Apis 200	Twice daily for 2 days, with placebo for the rest 28 days	1 month
19.08.2015	Felt mild pain in the abdomen once only, otherwise doing well.	placebo	1 month	1 month
23.09.2015	Status of patient further improved in respect of all symptoms and she continued to feel good with regular and normal menstruation.	placebo	1 month	Advised to report after 30 days
20.10.2015	Reported bleeding in last cycle quite profuse and pain recurred. Once urethral burning felt.	Apis 1 M	2 doses for 2 days, once daily, rest 28 days placebo	Advised to report after 30 days
18.11.2015	Reported remarkable improvement	Placebo	2 doses, once daily for 2 days Placebo for 1month	1 month, Advised for another USG.
Final visit 18.12.2015	No complaints, the patient was doing well and has not reported so far.	No medicine prescribed	Advised to report if any problem recurs in future	USG showed no abnormality. (Figure 1& 2)

Table 3: Details of symptoms, prescriptions, and improvements of the Patient No. 2 (Age 26, unmarried).

Visit	Symptoms	Medicine Given	Period of Taking Medicine	Advised to Come After
First Visit 12.03.2014	11/3/2014 Bulky right ovary and presence of right ovarian cyst [47mmX35mm] Pain right lower abdomen, menses alternately scanty and profuse, painful, with heaviness of lower abdomen, stinging pain; sense of tightness; bearing-down, as if menses were to appear; abdomen sore and tenderness felt at perineum region; leucorrhoea at onset of menstruation, vertigo on closing eyes; burning and soreness in urethra, urine scanty. Modalities-Aggravated by warmth, touch and pressure; feels better in open air, and cold bathing;	Apis 30	Twice daily for 8 days (at least 45 minutes to 1 hr before or after any food) and Placebo for another 22 days	Advised to report after 30 days
18.04.2014	Improvement of her pain in the abdomen.	Placebo	1 month	One month
20.05.2014	Feeling of weakness gradually improving; urinary symptoms also improved considerably.	Placebo	1 months	Advised to report after 30 days
17.06.2014	Right abdominal pain of moderate and bearable intensity with burning feeling in the urethra,	Apis 200	Twice daily for 2 days, with placebo for the rest 28 days	One month
21.07.2014	Felt mild pain in the abdomen once only otherwise doing well.	placebo	1 month	One month
29.8.2014	Presenting symptoms gradually improving, Status of patient further improved and she continues to feel good with regular and normal menstruation	placebo	1 month	Advised to report after 30 days
24.09.2014	Profused bleeding with pain in abdomen.	Apis 1 M	2 doses for 2 days, once daily, rest 28 days placebo	One month
23.10.2014	Doing well without any complaint.	placebo	One month	one month, Advised for another USG
Final visit 26.11.2014	Reported vast improvement	No medicine prescribed	Advised to report if any problem occurs in future	USG showed no abnormality. (Figure 3& 4)

Table 4: Details of symptom, prescriptions, and improvements of the Patient No. 3 (Age 16 years, unmarried).

Visit	Symptoms	Medicine Given	Period of Taking Medicine	Advised to Come After
First Visit 29.07.2014	Right ovary shows a cyst extending into the Pouch of Douglas. Size not mentioned. General Symptoms: Severe pain in right lower abdomen, suppressed menses and scanty also, with heaviness of right lower abdomen, stinging pain; sense of tightness; bearing-down, as if menses were to appear; abdomen sore and stinging pains, tenderness felt at perineum region; leucorrhoea at onset of menstruation, frequently amenorrhoea for two or three months; burning sensation during urination; burning and soreness in urethra, and urine scanty. feels very tired, vertigo on closing eyes, craving of milk, thirst less. Modalities: Aggravated by warmth, touch and pressure; feels better in open air, and cold bathing;	Apis 30	Twice daily for 8 days (at least 45 minutes to 1 hr before or after any food) and Placebo for another 22 days	Advised to report after 30 days
25.08.2014	Pain right abdomen gradually improving, feeling of weakness gradually improving; urinary symptoms also improved considerably.	Placebo	1 month	One month
21.09.2014	Reappearance of right abdominal pain of bearable intensity with burning feeling in the urethra, Menstrual flow normal last month.	Apis 200	Twice daily for 2 days, with placebo for the rest 28 days	One month
15.10.2014	Symptoms that bothered her gradually improving, Status of patient further improved and she continued to feel good with regular and normal menstruation, no pain felt in this month.	placebo	1 month	One month
16.11.2014	Reported painful and profuse bleeding in the last menstrual cycle.	Apis 1 M	2 doses for 2 days, once daily, rest 28 days placebo	One month
19.12.2014	Doing well without any undesirable symptoms. Advised to visit if any symptom recurs.	placebo	One month	one month, Advised for another USG
Final visit 6.01.2015	No complaints till now and have not visited so far.	No medicine prescribed	Advised to report if any problem occurs in future	USG showed no abnormality. (Figure 5& 6)

Table 5: Hormonal parameters of each patient.

Sl. No	Blood Parameter	Pt. No - 1		Pt. No - 2		Pt. No - 3		Significant Level Between BM vs. AM
		BM	AM	BM	AM	BM	AM	
1.	LH mIU/ml	15.04	5.05	16.50	5.25	17.56	7.56	***
2.	FSH mIU/ml	4.70	4.90	4.55	4.15	6.55	7.16	NS
3.	LH:FSH Ratio	3.2:1	1.03:1	3.62:1	1.26:1	2.68:1	1.05:1	***
4.	S. Free Testosterone pg/ml	4.7	3.05	4.25	4.60	5.47	3.25	*
5.	DHEAS µg/ml	180.22	189.06	206.58	210	201.23	195.22	NS
6.	Prolactine ng/ml	12.89	11.90	9.15	10.20	12.36	9.02	NS
7.	E ₂ (Estradiol) pg/ml	209.34	250.08	150.22	187.88	187.02	201.53	NS
8.	Insulin (F) µIU/ml	12.87	14.65	8.20	8.75	14.25	9.25	NS
9.	Insulin (PP) µIU/ml	90.55	82.44	100.03	96.45	95.22	89.25	NS
10.	Glucose (F) mg/dl	105.87	92.14	96.47	90.46	110.21	105.25	NS

p<0.05*, p<0.001***, NS= Non significant, BM= Before medicine, AM= After medicine

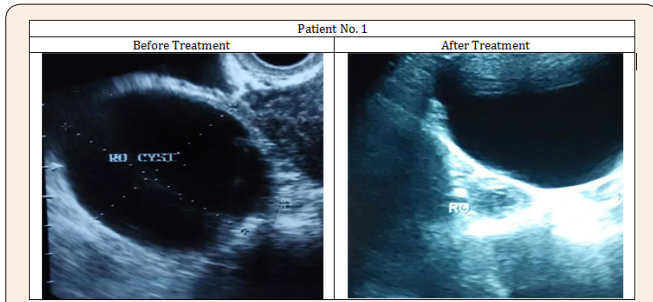


Figure 1: Images of Ultra-sonography of the patient No. 1 showing removal of the cyst from right ovary.




Figure 2: Ultra-sonographic reports of the patient No. 1 showing removal of the cyst from right ovary.

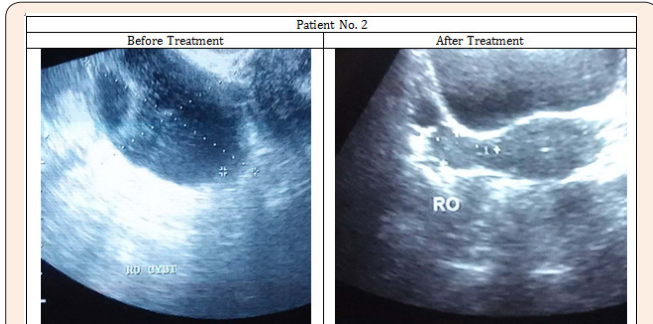


Figure 3: Images of Ultra-sonography of the patient No. 2 showing removal of the cyst from right ovary.

Results and Discussion

From analysis of the change in ameliorating symptoms or recurrence of unwanted symptoms, the suitable potencies were prescribed; initially all three patients received the 30C potency and advised to come after one month. In all the patients, amelioration of symptoms like irregularity of menstruation, reduction in intensity of pain was noticed after administration of the 30C potency to a varying degree. Whenever there was a recurrence of symptoms after a period of steady amelioration, the next higher

potency was chosen. And when all the symptoms were totally gone gradually, the final USG was advised for checking whether the cysts had also been removed. In all the patients, USG revealed presence of the cysts before drug administration, but finally in all the cases there was no more any trace of the cysts.




Figure 4: Ultra-sonographic reports of the patient No. 2 showing removal of the cyst from right ovary.

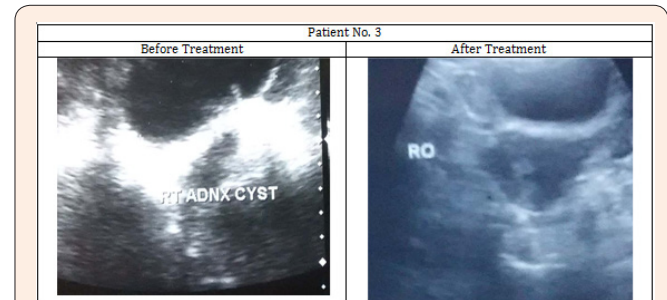


Figure 5: Images of Ultra-sonography of the patient No. 3 showing removal of the cyst from right ovary.




Figure 6: Ultra-sonographic reports of the patient No. 3 showing removal of the cyst from right ovary.

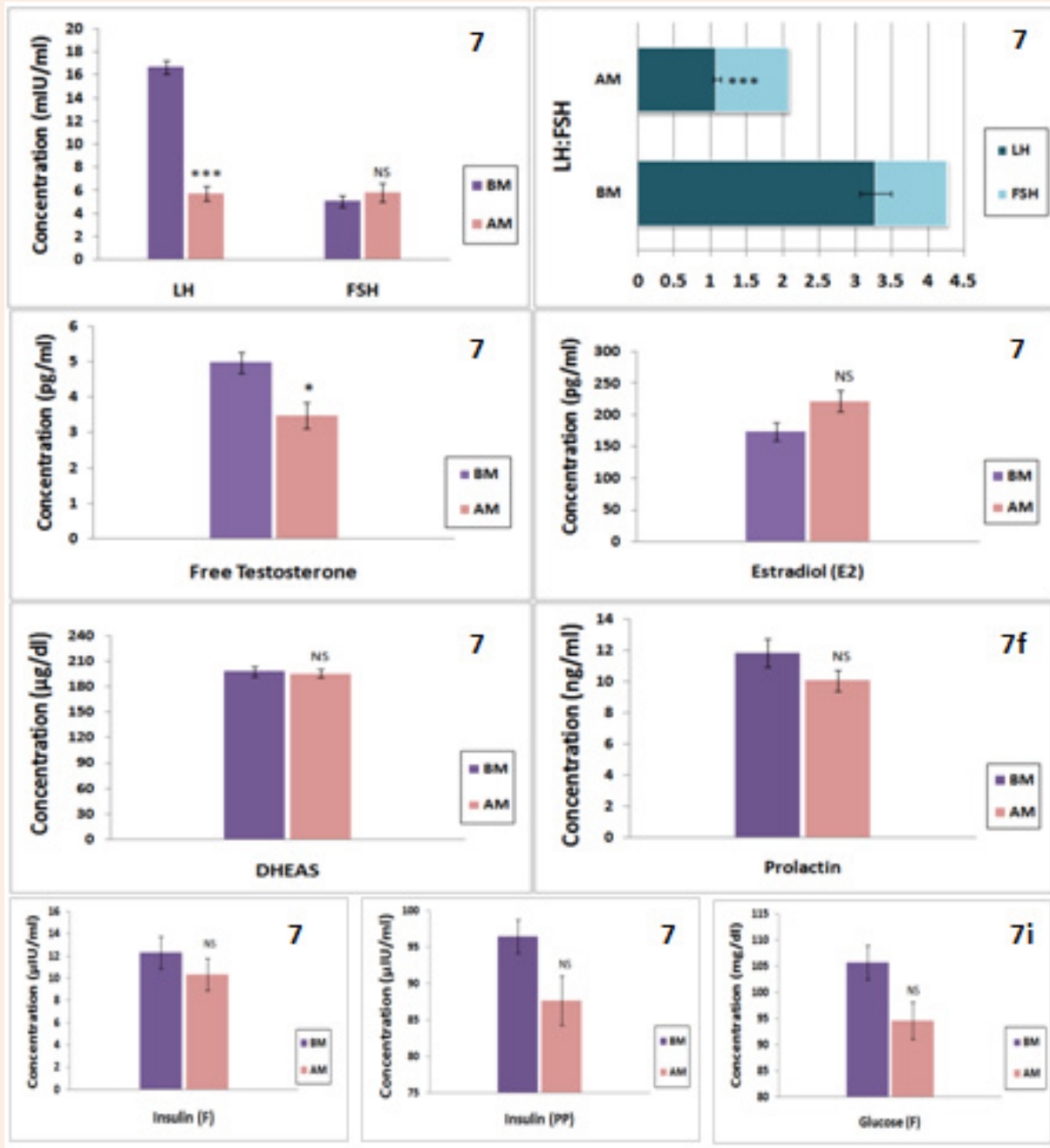


Figure 7: Graphical representations of hormonal parameters.

In order to correlate if hormonal activities in the patients during the treatment were also modulated we advised the patients to check up if there were any hormonal changes associated with the abolition of the cysts. The data in respect of certain probable hormones known to be associated with the formation/removal of cysts were therefore also recorded, both prior to and after completion of drug administration. The results of changes of the different important hormones have been enlisted in Table

5 and represented in the bar diagrams to show if the changes were statistically significant (Figure 7). An appraisal of the data would reveal that significant changes in the important hormones like LH (highly significant $p < 0.001$), LH/FSH ratio ($p < 0.001$), and pre-testosterone ($p < 0.05$) occurred during the period of drug administration to the end of the treatment period. These hormonal changes are significant in that the lower level of LH as well as the LH/FSH ratio are considered favourable factor for

promoting fertility and other associated phenotypic problems [8]. Apart from these remarkable changes, there were also indication of favourable changes in certain hormones like estradiol, prolactin, DHEAS and insulin (both fasting and pp) although these changes were statistically insignificant. The glucose level for both fasting and pp in all the patients were favourably modulated, though they did not show statistical significance, partly because of the range which is considered normal for a person varies (eg. between 80 and 110/120 mg/dl). Similarly all the symptoms had almost gone away in all three patients and their final USG also confirmed removal of their cysts.

Conclusion

In conclusion, the results of the present study would indicate that proper selection of the homeopathic remedy matching the totality of symptoms and in consultation with the Kent's rubric [4] can remove cysts from the ovary without any surgical intervention and this can serve as an alternative option, at least in patients where surgery also has some risk or undesirable. This can curtail cost of treatment for the economically under-privileged section of the people as well, particularly residing in remote areas where medical amenities and infra-structural facilities for doing surgery are by and large are still unavailable [9].

Acknowledgement

DD conveys his gratitude to the Principal, Bengal Homeopathic Medical College and Hospital, Asansol, to the Principal of Mahesh Bhattacharyya Homeopathic Medical College and Hospital, Howrah and to the WB University of Health Sciences for allowing him to carry out this work as a part of his Ph.D programme. ARK-B is thankful to UGC for awarding Emeritus Fellowship to him.

References

1. OWH (2015) Ovarian cysts.
2. Benifla JL, Hauuy JP, Guglielmina JN, Walker-Combrouze F, Bocquet L, et. al. (1992) Celioscopic removal of cysts: a fortuitous histological discovery of an ovarian carcinoma. A case report. *J Gynecol Obstet Biol Reprod* 21(1): 45-49.
3. Renolleau C, Daraï E, Madelenat P, Benifla JL, Neu AM (1997) Laparoscopy and ovarian cancer: dangers and precautions. *Contracept Fertil Sex* 25(9): 5-10.
4. Allen HC (2002) Keynotes and characteristics with comparisons of some of the leading remedies of the Materia Medica with nosodes. (2nd edn), B Jain Publishers Pvt. Ltd., New Delhi, India.
5. Boericke W (2002) Pocket Manual of Homoeopathic Materia Medica & Repertory: Comprising of the Characteristic and Guiding Symptoms of All Remedies (clinical and Pahtogenetic [sic]) Including Indian Drugs. (2nd edn), Jain Publishers (P) Ltd., New Delhi, India.
6. Kent JT (1985) Lectures on Homeopathic Materia Medica: Together with Kent's "new Remedies" Incorporated and Arranged in One Alphabetical Order. (2nd edn), B Jain Publishers Pvt. Ltd., Noida, India.
7. Das D, Das I, Das J, Kayal SK, Khuda-Bukhsh AR (2016) Efficacy of two traditionally used potentized homeopathic medicines, *Calcarea carbonica* and *Lycopodium clavatum*, used for treating PCOS patients: I. Effects on certain important external guiding symptoms. *TANG [HUMANITAS MEDICINE]* 6(1): 1-6.
8. Das D, Das I, Das J, Kayal SK, Khuda-Bukhsh AR (2016) Efficacy of two commonly used potentized homeopathic drugs, *Calcarea carbonica* and *Lycopodium clavatum*, used for treating polycystic ovarian syndrome (PCOS) patients: II. Modulating effects on certain associated hormonal levels. *TANG [HUMANITAS MEDICINE]*. 6(1): 1-7.
9. Banaszewska B, Spaczyński RZ, Pelesz M, Pawelczyk L (2003) Incidence of elevated LH/FSH ratio in polycystic ovary syndrome women with normo- and hyperinsulinemia. *Rocz Akad Med Białymst* 48: 131-134.